Medical Endoscopy Report

Patient Information

Patient Name: ABDUL ASEES

Patient ID: ABDUL ASEES_66875_RP241009_024107

Report Date: 2025-12-04 12:53:35

Endoscopy Images

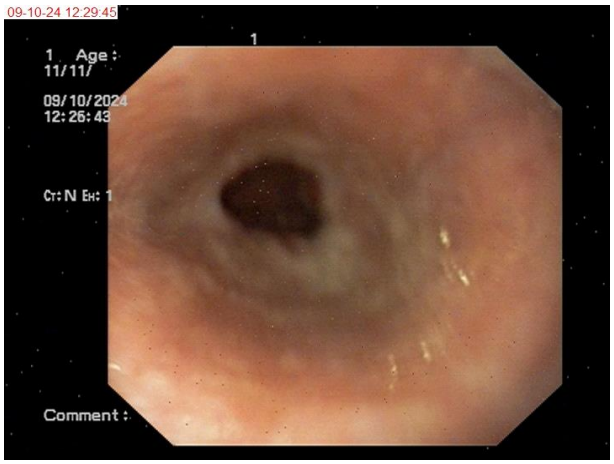

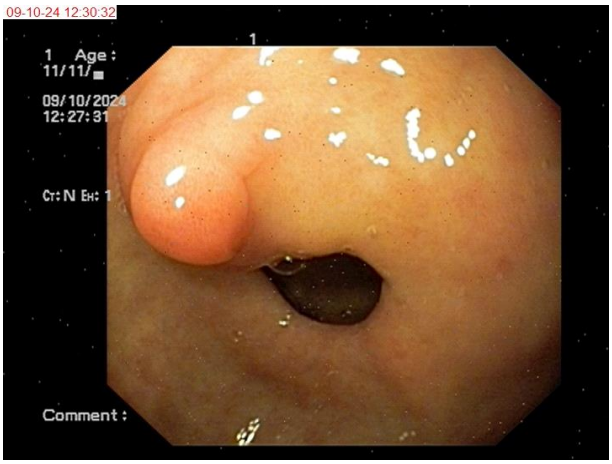

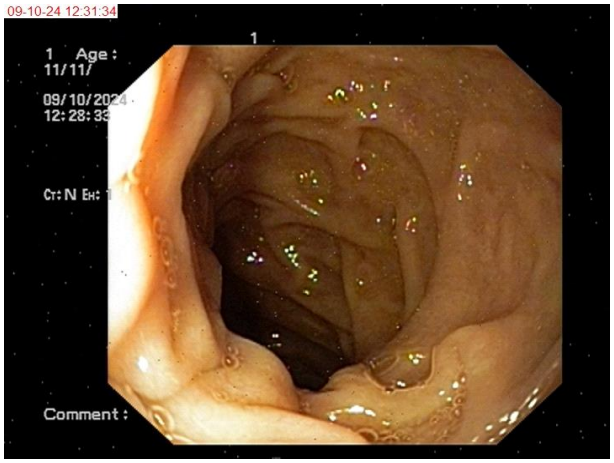

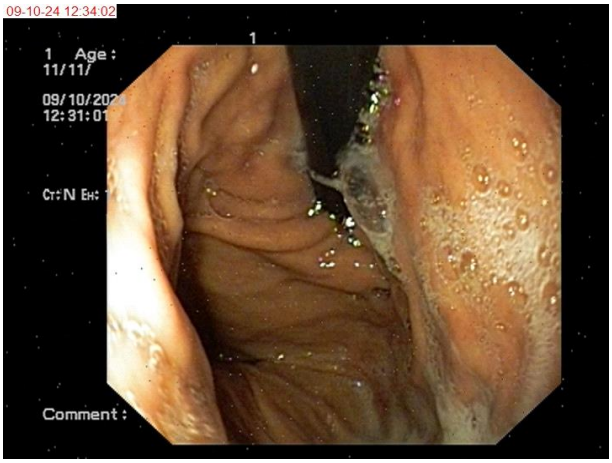

Findings

Indication: CLD-S/P EVL-Relook 2 weeks after 1st session 1.1.2023 10.10.2023 10.10.2023 10.10.2023 10.10.2023 10.10.2023 10.10.2023 10.10.2023 10.10.2023 10.10.2023 10.10.2023 10.10.2023 10.10.2023

Scope Passed Upto:	D2 mucosa without ulcers/ erosions/ luminal narrowing .Scope passed upto D3 .No resistance encountered during scope passage .Surrounding mucosa appears normal .No active bleeding at present .No immediate complications .Post procedure patient stable and tolerating liquids and semi liquids .Post procedure patient was discharged .Post procedure patient was given follow up appointment .Post procedure patient was given anti RT and anti HB injections .Post procedure patient was given 4.8 ml of ten
Premedication:	10% XYLOCAINE ANTRUM AND PYLORUS WITH SURROUNDING NODULARITY AND ULCERATION IN D1 AND D1 NODULARITY AND ULCERATION IN D1 AND D1 NODULARITY AND ULCERATION IN D1 AND D1 NODULARITY AND ULCERATION IN D1 AND D1 NODULARITY AND ULCERATION IN D1 AND D1 NODULARITY AND ULCERATION IN D1 AND D1 NODULARITY AND
Esophagus:	Normal mucosa without ulcers/ erosions/ luminal narrowing with normal peristalsis and distensibility noted .No foreign body seen in the esophagus .No esophageal varices seen .No altered blood seen in the lumen .No luminal blood seen in the esophagus .No foreign body seen in the esophagus .No altered blood seen in the lumen .No luminal blood seen in the esophagus .No foreign body seen in the esophagus .No altered blood seen in the lumen .No luminal blood
Ge Junction:	40CMS and edematous and erythematous mucosa noted. No ulcer/ tear/ growth noted in the GE junction .Biopsy taken from the GE junction .GE junction lax .No food or fluid stasis noted in the stomach .No altered blood noted in the lumen .No active ooze noted in the stomach .No luminal blood noted in the stomach .No ulcer/ tear/ growth noted in the GE junction .No luminal blood noted in the stomach .No active ooze
Stomach:	No ulcers ,erosions or altered blood in lumen. A small clean based ulcer of size 0.5cm without active ooze seen at GE junction . No luminal blood or sites of ooze seen in the stomach. All regions show normal peristalsis and distensibility except for small decreased peristalsis in the proximal antrum. No luminal blood or sites of ooze seen in the duodenum. All regions show normal peristalsis and distensibility except for small decreased peristalsis in the proximal antrum. No luminal blood or
Fundus:	Normal mucosa. No ulcers/ growth/ varices/ luminal blood or ooze / areas of active ooze in the fundus of stomach or proximal antrum at the time of endoscopy on 11/11/24 at 10.30am at the age of 38 years. No altered blood in the lumen of stomach or proximal antrum at the time of endoscopy on 11/11/24 at 10.30am at the age of 38 years. No altered blood
Body:	Normal mucosa without ulcers/ erosions/ luminal narrowing . Normal distensibility and peristalsis noted . No altered blood in the lumen . No active ooze . No luminal blood . No areas of ooze in the proximal body of stomach . No areas of ooze in the fundus . No areas of ooze in the cardia . No areas of ooze in the proximal antrum . No areas of ooze in the distal antrum . No areas of ooze in the p
Antrum:	Normal mucosa. No ulcers/ growth/ luminal blood/ areas of active ooze or sites of ooze. All stomach regions show normal distensibility and peristalsis and no mass lesion/ thickening noted in the proximal and fundal regions. Normal mucosa without ulcers/ erosions/ luminal blood in the antrum and pylorus regions of the stomach . No altered blood in the lumen . No active ooze or sites of ooze noted in the stomach .

Pylorus:	Normal mucosal folds, normal peristalsis. No ulcers/ erosions/ growth. Normal distensibility and compressibility of stomach noted. No luminal blood or sites of ooze noted in the stomach or duodenum mucosa in the present study . No active ooze noted in the present study . No luminal blood or sites of ooze noted in the present study . No active ooze noted in the present study . No luminal blood or sites of ooze noted in the present study . No active o
Duodenum:	D1: Normal | D2: Normal mucosa. No ulcers/ growth/ luminal blood/ areas of active ooze or areas of necrosis. All stomach regions show normal distensibility and peristalsis and proximal and distal antrum show normal mucosal folds and no ulcers/ erosions/ luminal blood or areas of necrosis. All regions of stomach show normal peristalsis and distensibility and no areas of active ooze or areas of necrosis. All stomach regions show normal
Rut:	Not taken D1 mucosa was in contact with the scope and could not be taken across the GE junction D1 mucosa was in contact with the scope and could not be taken across the GE junction D1 mucosa was in contact with the scope and could not be taken across the GE junction D1 mucosa was in contact with the scope and could not be taken across the GE junction D1 mucosa was in contact with the scope and could not be taken across the GE junction D1 mucosa was in contact with the scope and
Biopsy:	Not taken antrum and body . Taken from antral nodularity and D2 ulcer margins . From antrum , a single nodularity of size 1x1cm with overlying erythematous mucosa seen in the antrum 1cm below incisura . From D2 , a single nodularity of size 1x1cm with overlying erythematous mucosa seen in the D2 1cm below incisura . Both biopsies taken with biopsy forceps
Impression:	ANTRAL GASTRITIS RUT- BIOPSY TAKEN FROM ANTRUM AND D2 FOR CBNAAT TAKEN PLAN : COLONOSCOPY AND IMAGING IF FURTHER HB FALL OR BLEED PBN AND COLONOSCOPY AND IMAGING IF FURTHER HB FALL OR BLEED PBN AND COLONOSCOPY AND IMAGING IF FURTHER HB FALL OR BLEED PBN AND COLONOSCOPY AND IMAGING IF FUR